Ergometrisk stressekkokardiografi

Videregående kurs i ekkokardiografi, Trondheim 2019

Helge Skulstad

Seksjonsoverlege

Hjerteultralydseksjonen

Kardiologisk avdeling, RH, OUS

helsku@ous-hf.no

Oslo universitetssykehus

Disposisjon

- Innledning
- Metode
- Bruk ved diverse hjertesykdommer:
  - HCM/HOCM
  - Koarktasjon og andre medfødte hjertefeil
  - Klaffeinsuffisienser og stenoser
  - Diastolisk dysfunksjon og HefPEF
  - Pulmonal hypertensjon
  - Andre medfødte hjertefeil
- Oppsummering

Ergoekko

- Vurdere de patologiske forholds betydning for pasientens funksjonsnivå.
- Bestemme de patologiske forholds betydning for endringer i hemodynamiske og funksjonelle forhold under belastning.
- Bestemme belastningsinduserte endringer i de strukturelle patologiske forhold.

Ergoekko

- Sykkelbenk med pasienten i halvt sittende skråleie.
- BT- og EKG-monitorering.
- 20 W + 20 W hvert 2 minutt.
- Ekkoopptak hvert annet minutt.

Tidsskr Nor Legeforen 2012

HCM/HOCM og ergoekko

Gradient i LVOT > 30 mmHg i hvile eller > 50 mmHg ved belastning er intervensjonssgrense

Mange pasienter med HCM har ikke gradient i hvile, men får det ved belastning

Medikamentelt stress kan ikke brukes (20% uten hypertrofi får gradient)

Vurder også økning i SAM, MI, Trp og endring i VV-funksjon.

HCOM

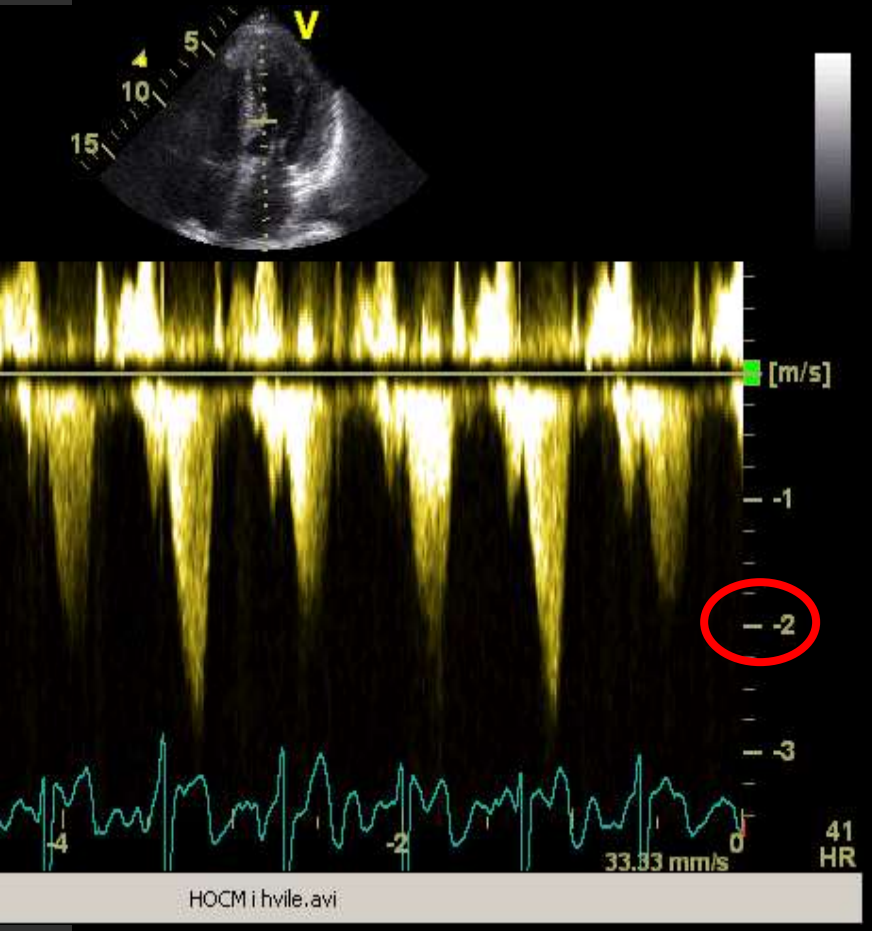

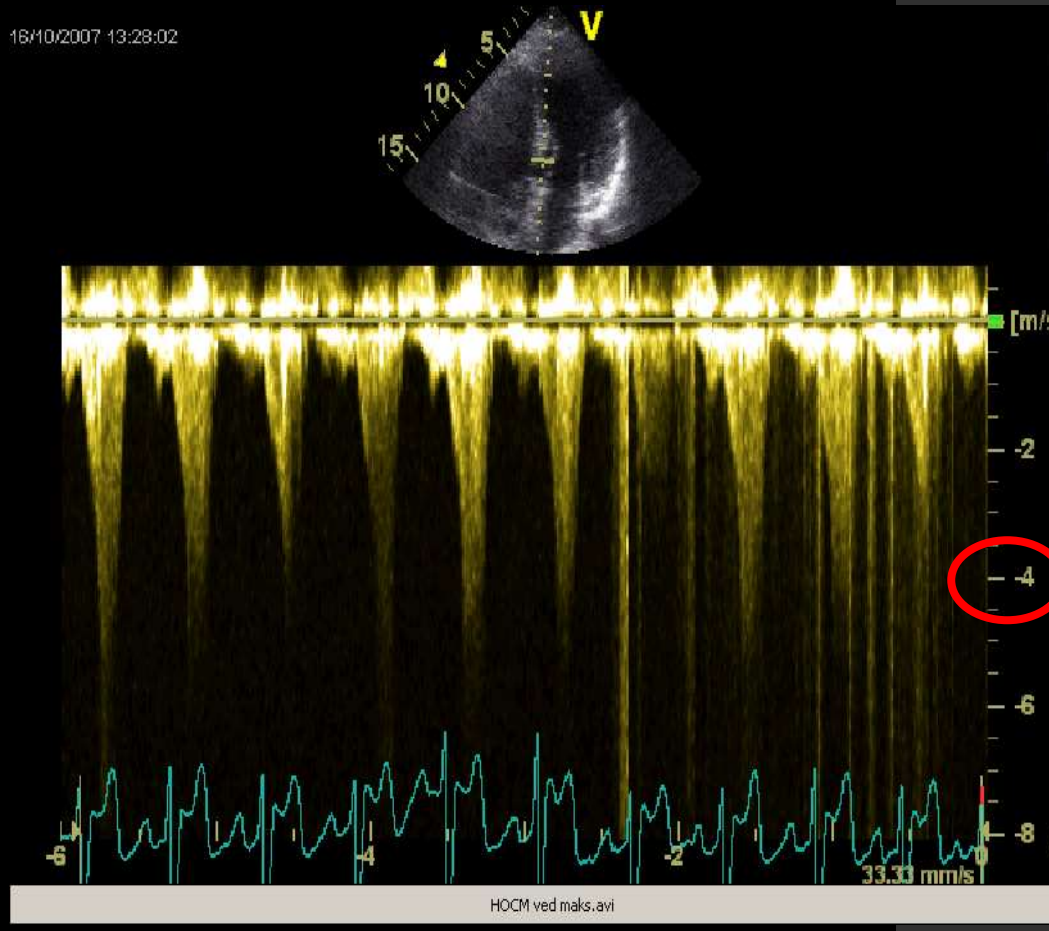

Hvile

Maksimal belastning

HCM/HOCM og ergoekko

Vurdere VV-funksjon. Latent svikt kan påvises hos opp til 40 % med HCM/HOCM med normal funksjon i hvile.

Metoden kan også brukes til å skille ut pas med idrettshjerte fra HCM/HOCM. Idrettshjerte pas har ikke økning i gradienten og har ofte hyperdynamisk repsons.

Coarctatio aorta

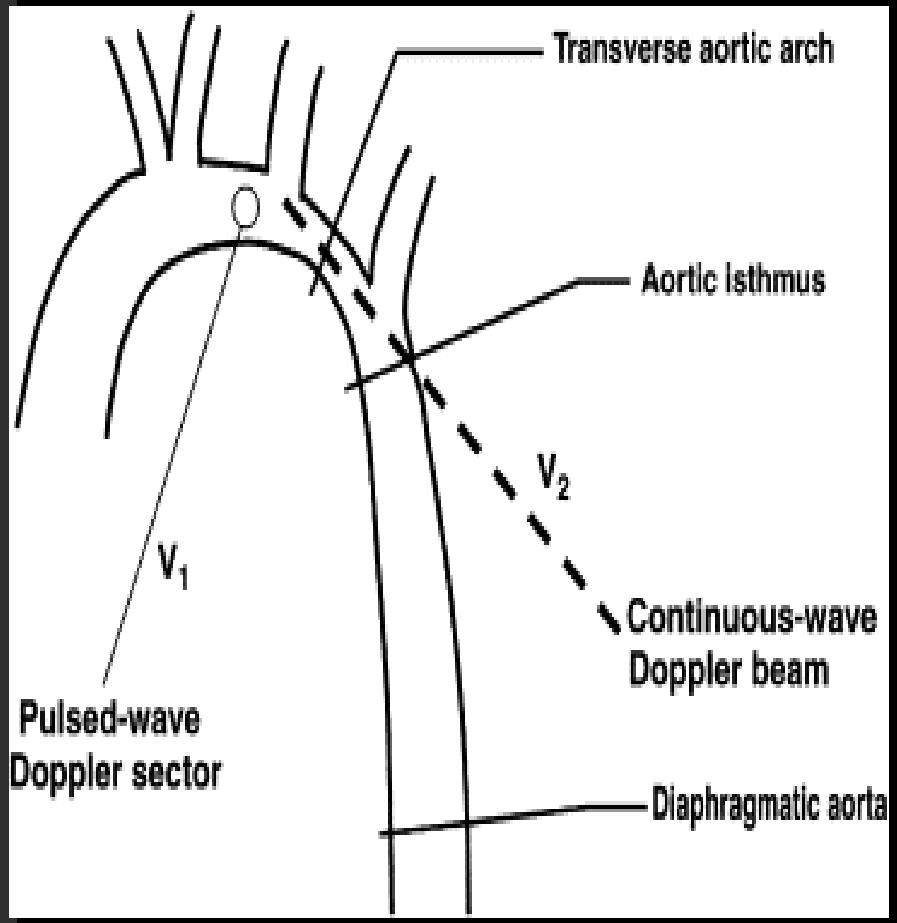

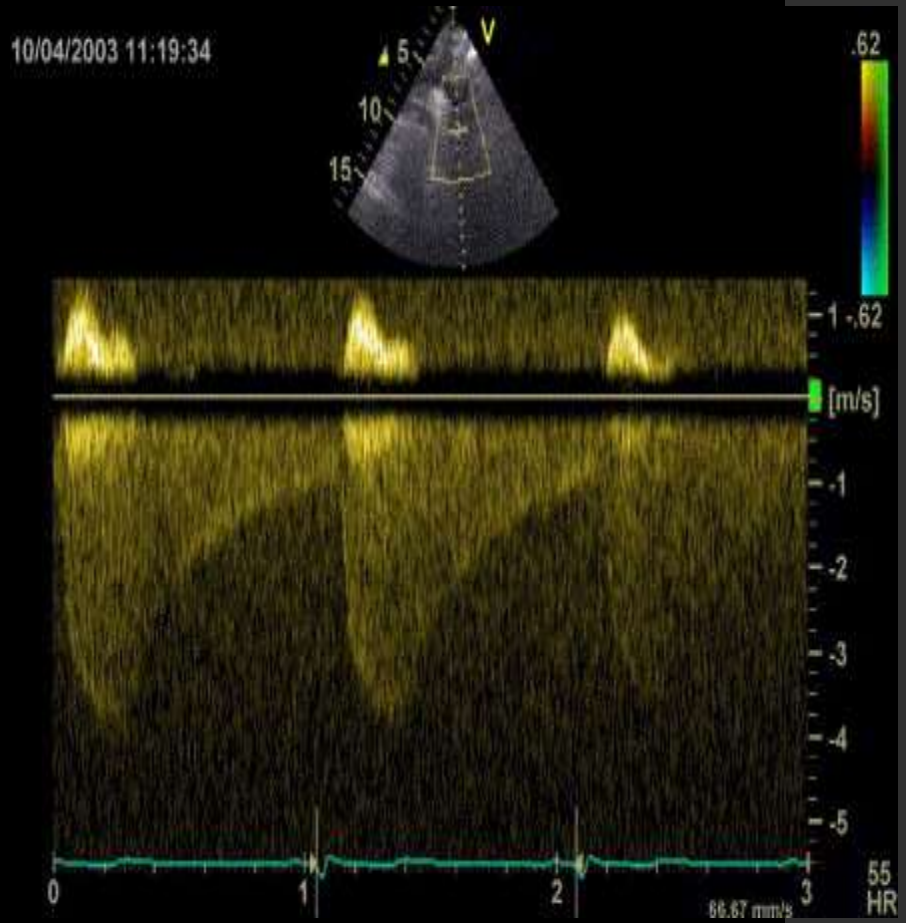

Giardini et al. Int J Cardiol 2007. 119. 21-27.

Recoarctasjon etter ende til ende anastomose

Vriend and Mulder. Int J Cardiol. 2005 (101). 399-406.

(Re-) coarctatio aorta

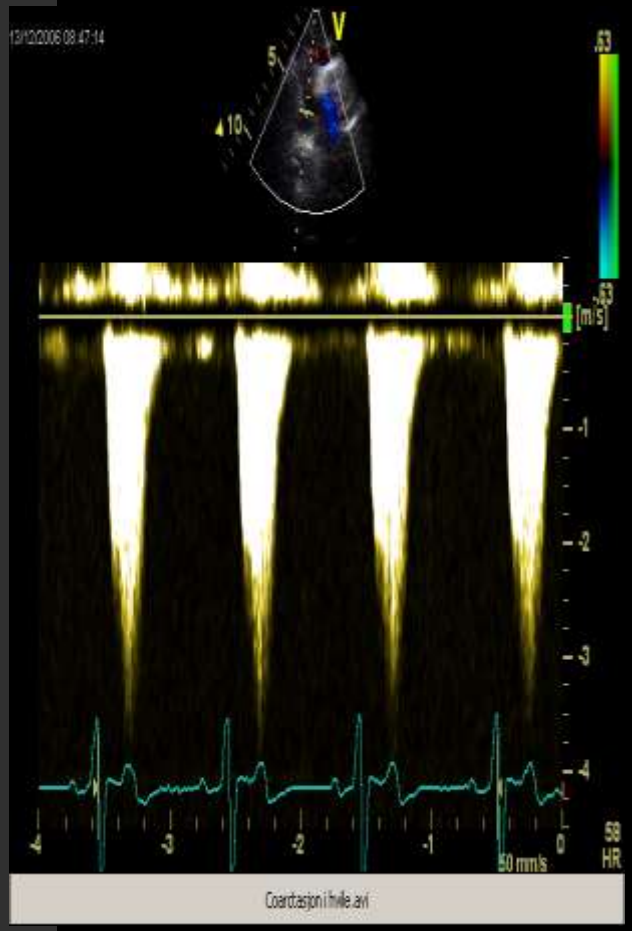

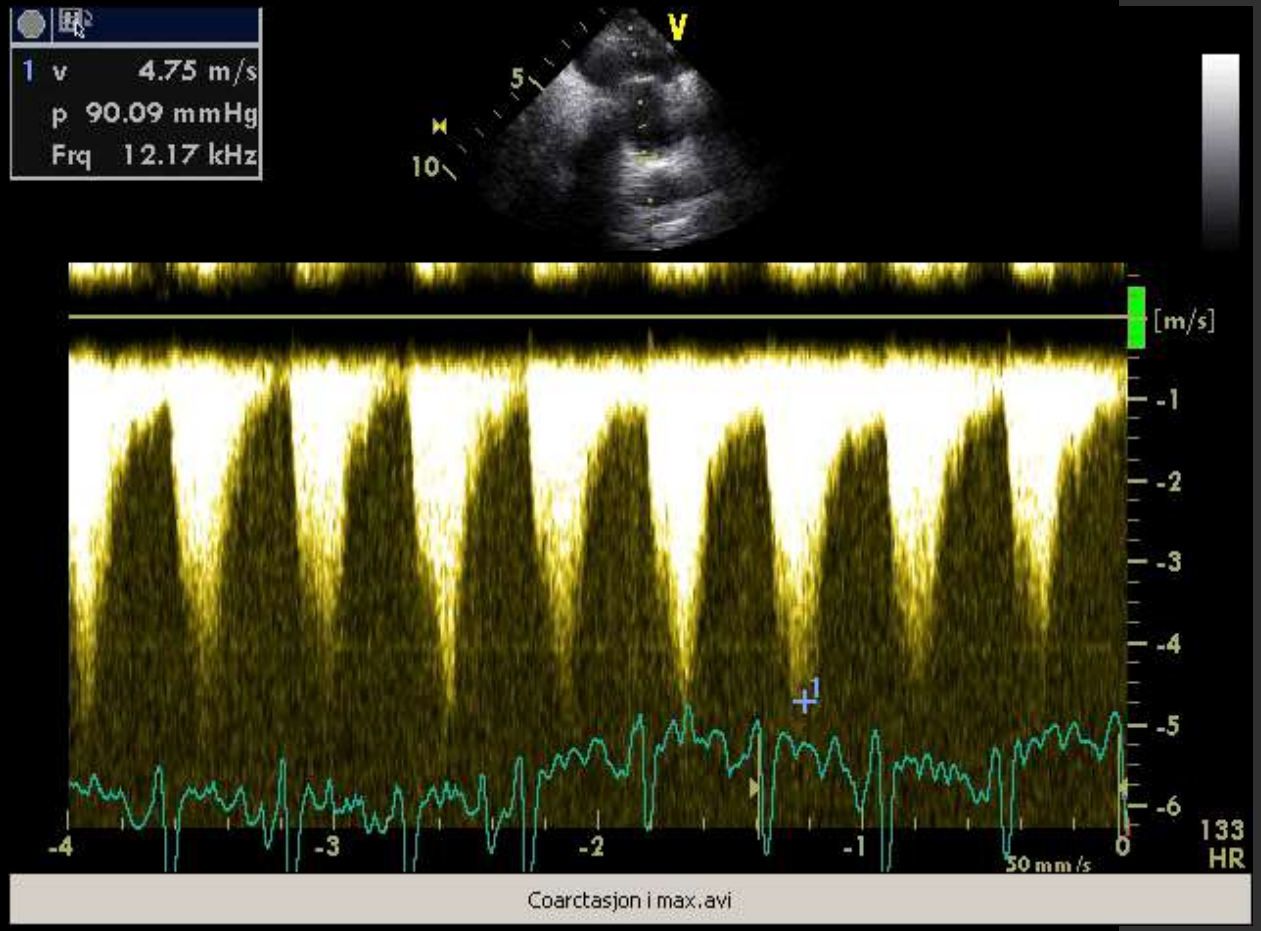

Hvile

Maksimal belastning

Mitralstenose - Hvileopptak

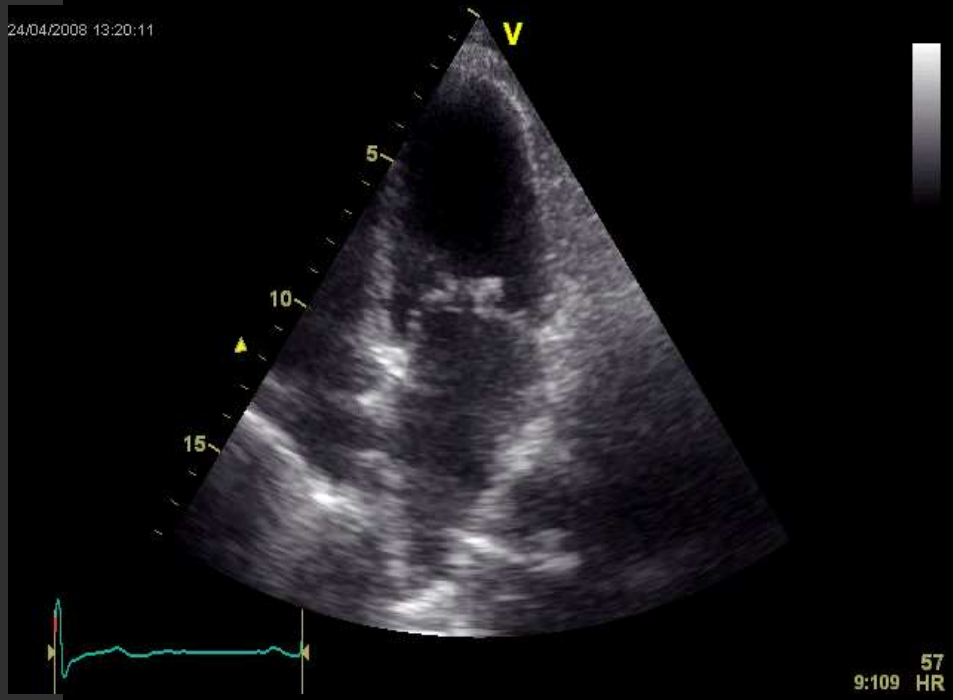

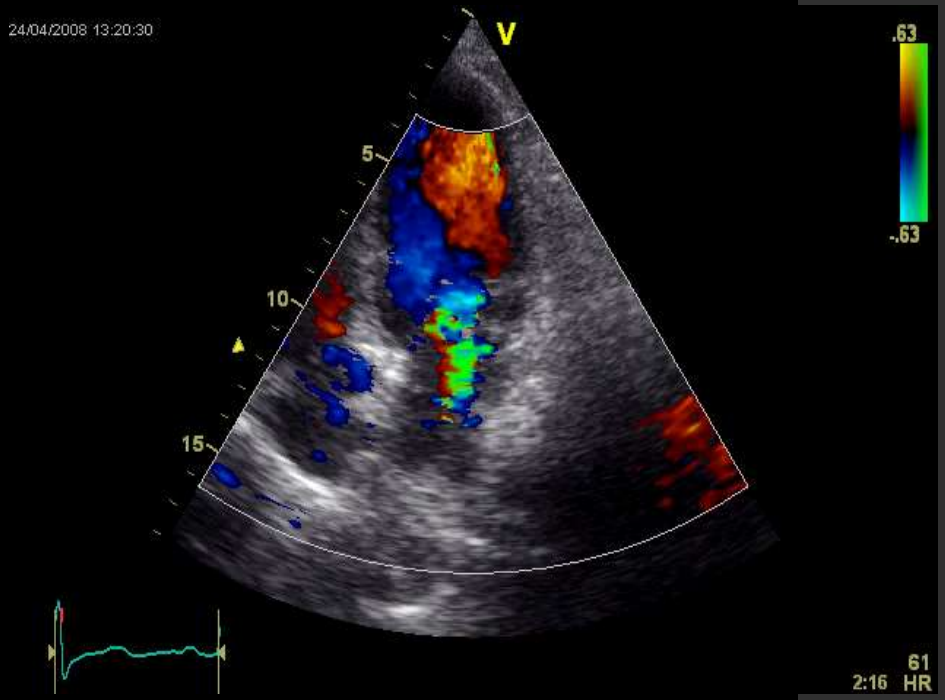

MS
Hastigheter - Gradienter

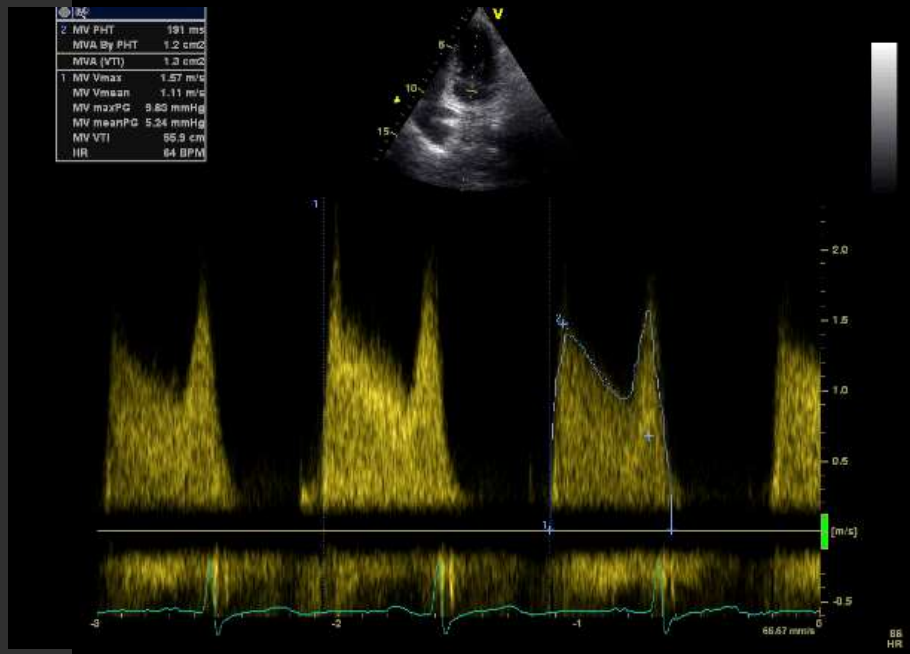

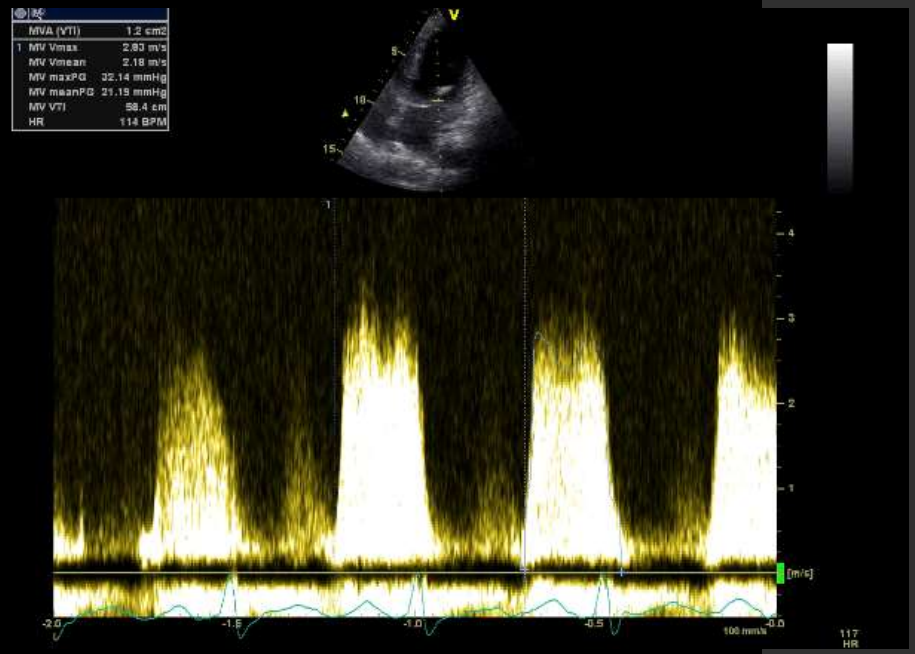

Hvile:
10/5 mmHg

Maks belastning:
32/21 mmHg

MS - Trp

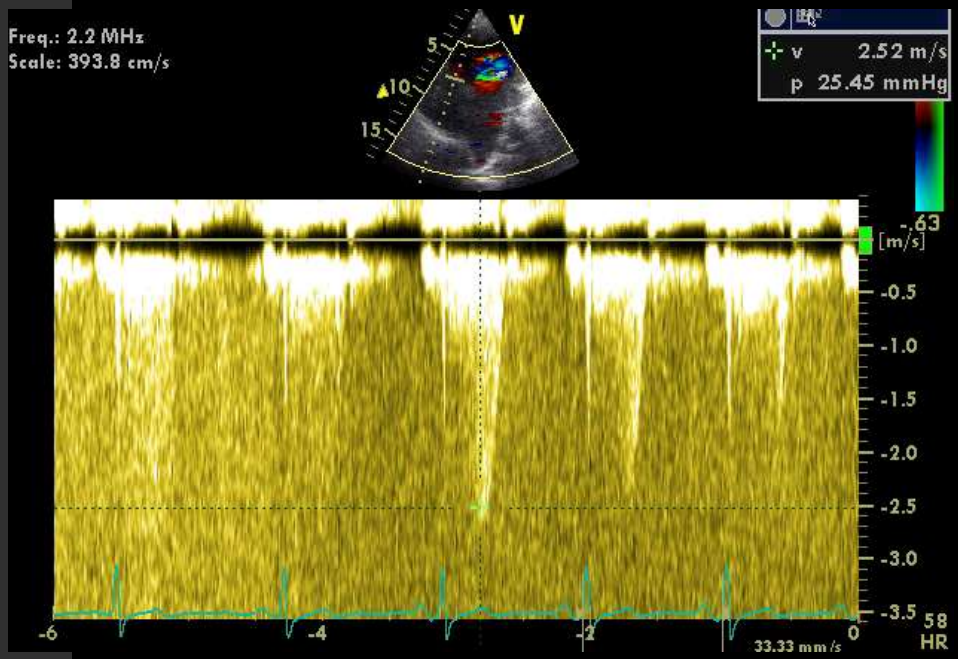

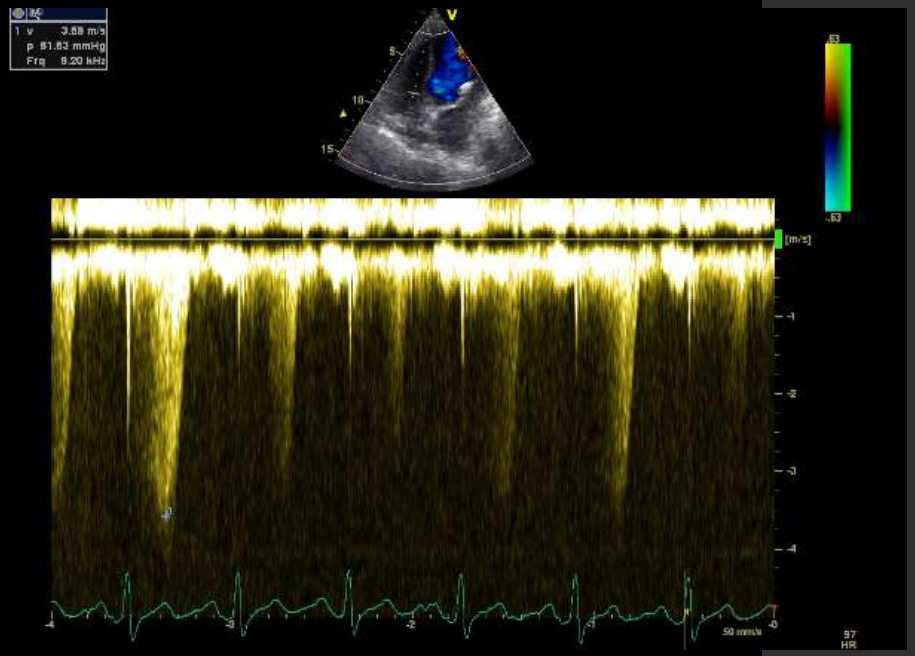

Hvile:
25 mmHg

Maks belastning:
52 mmHg

Mitralstenose/MVR mismatch

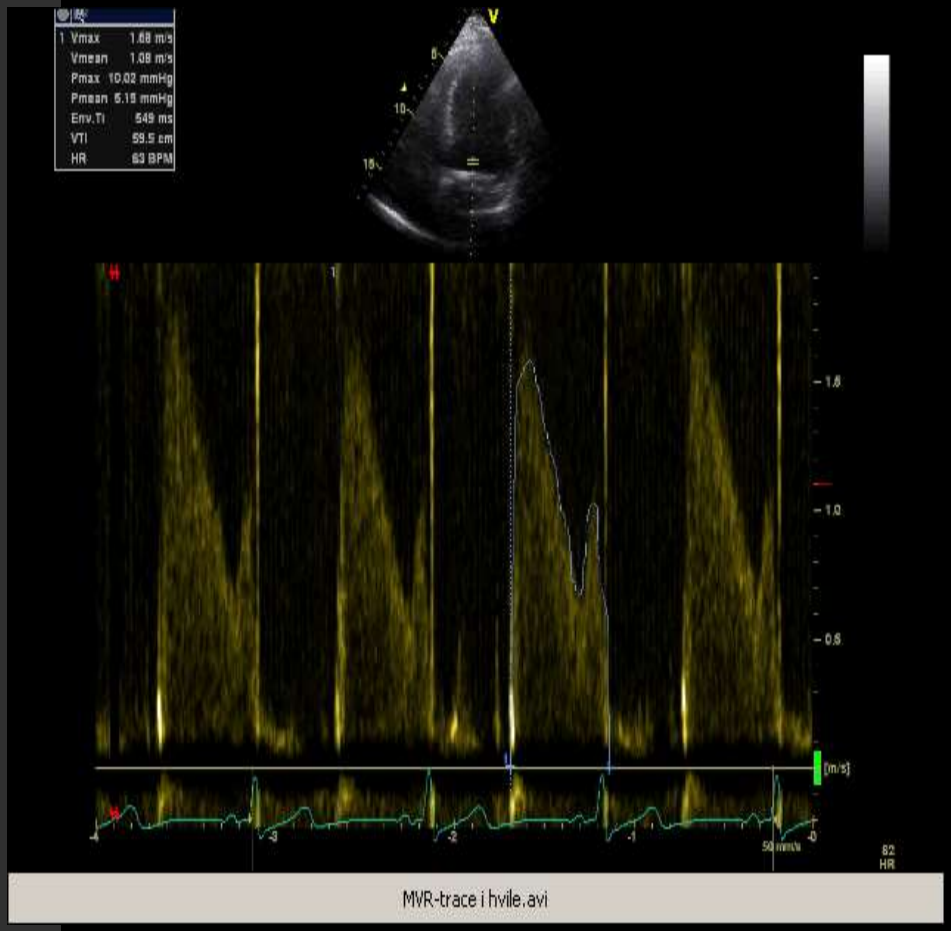

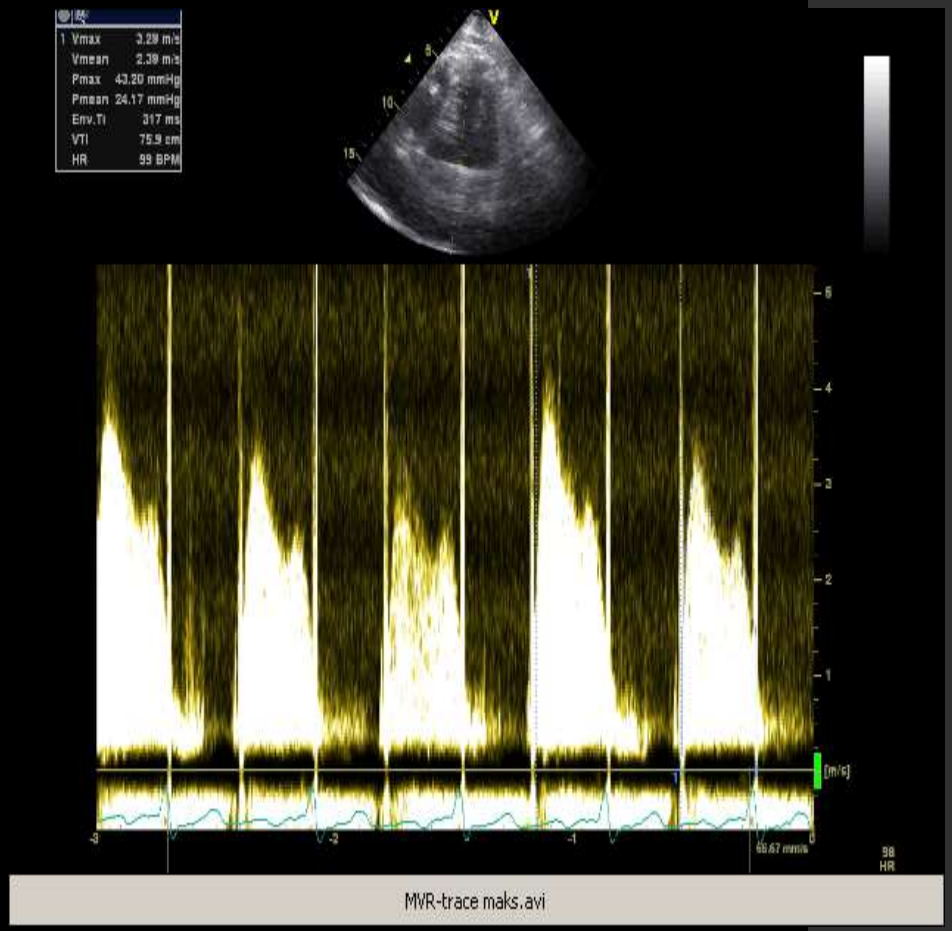

Hvile:
10/5 mmHg

Maksimal belastning:
43/24 mmHg

Mitralstenose/MVR mismatch TRP

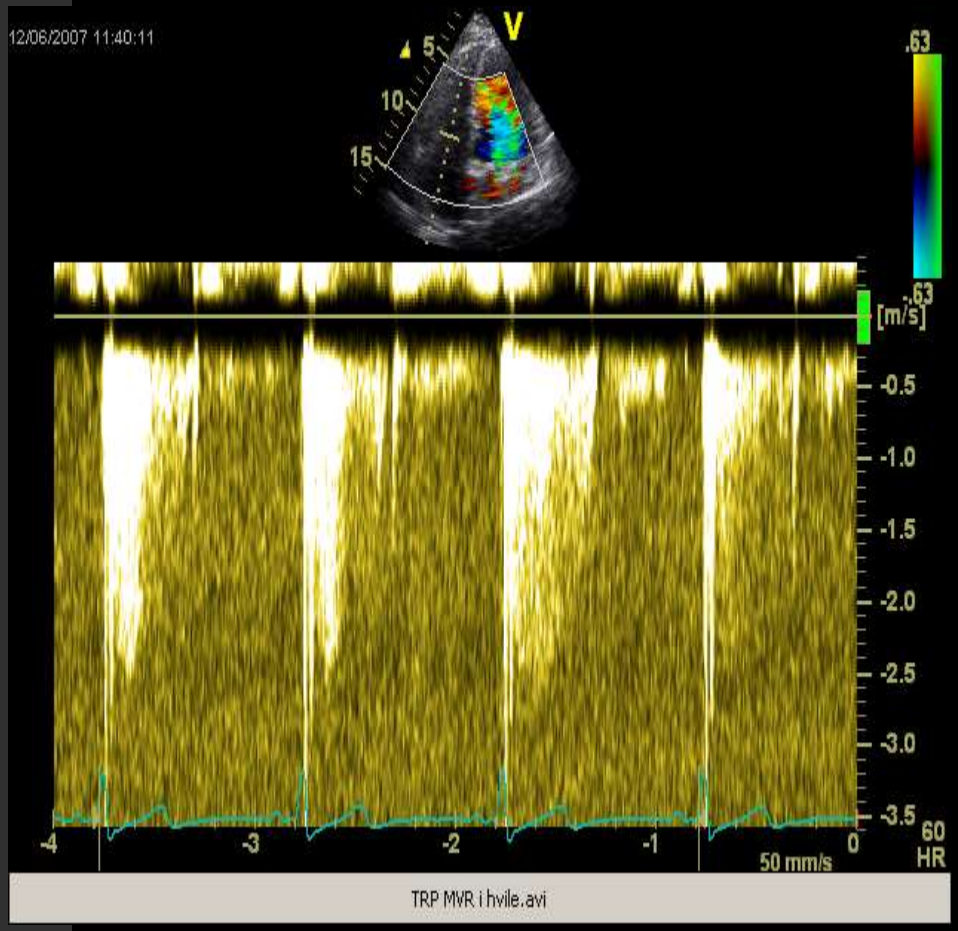

Hvile: 25 mmHg

Maksimal belastning: 60 mmHg

MS og ergoekko; Anbefalinger:

American Society of Echocardiography:

Hemodynamisk betydningsfull stenose:

Dyspnoe ved belastning

Mean MVgr øker til > 15 mmHg

Sys AP-trykk øker til > 60 mmHg

European Society of cardiology:

"Stress testing is indicated in patients with no symptoms or symptoms equivocal or discordant with the severity of MS.

Dobutamine or, preferably, exercise echocardiography may provide additional information by assessing changes in mitral gradient and pulmonary pressures"

MI: Dynamiske endringer

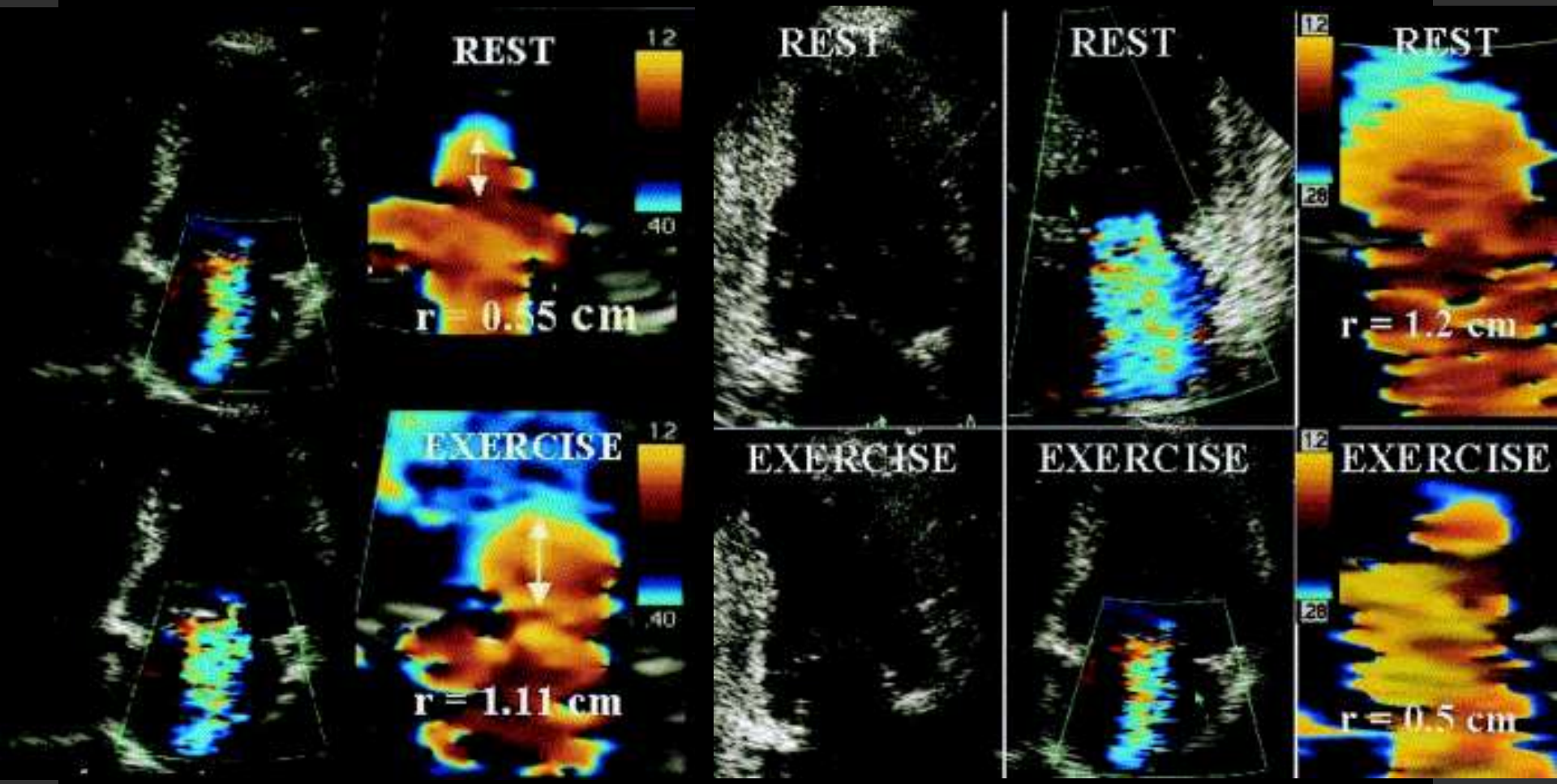

Lancelotti et al. JACC 2003;42:1921-8

Mekanismer for funksjonell mitralinsuffisiens

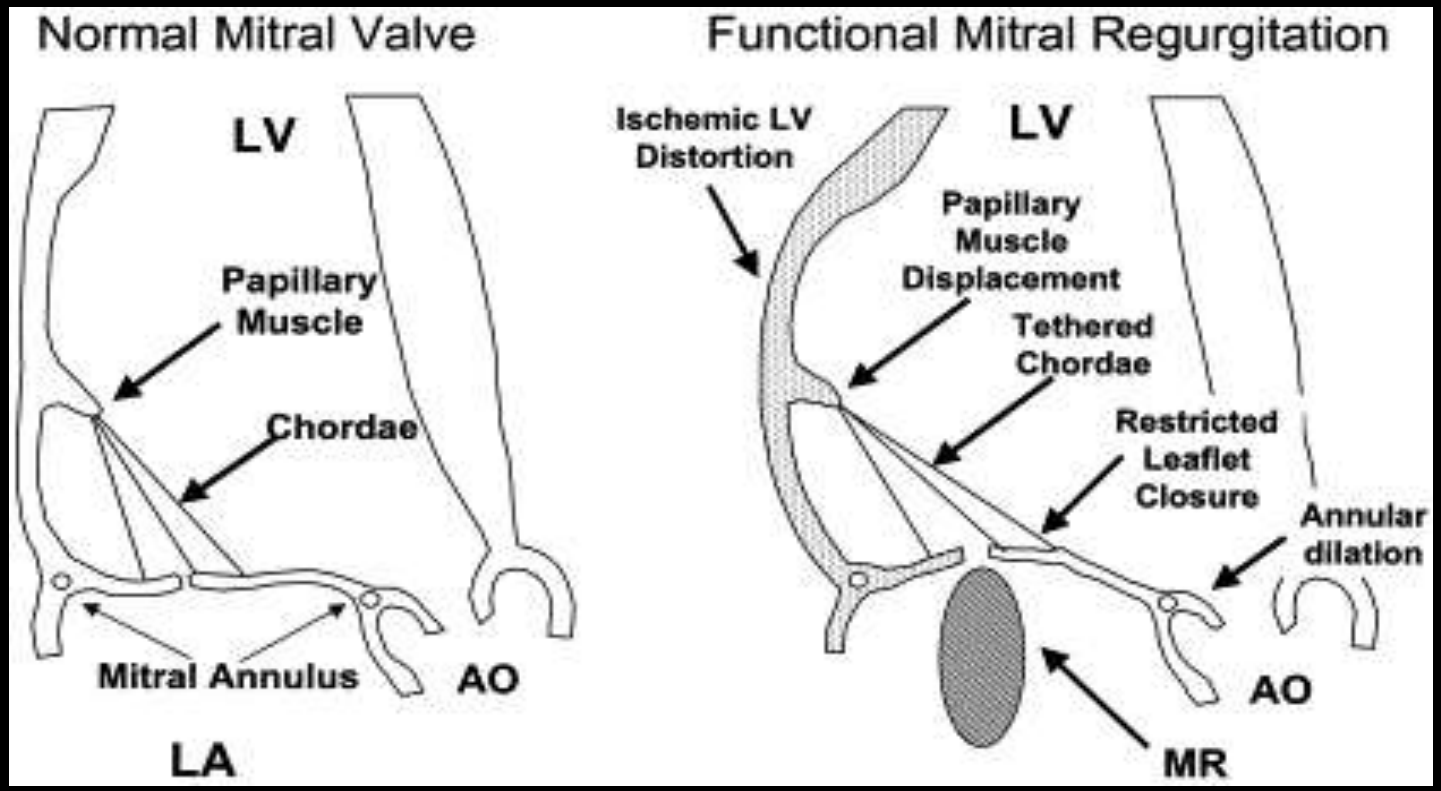

Levine and Hung.
Ischemic mitral regurgitation, the dynamic lesion: clues to the cure
JACC 2003;42:1921-8

MI(Iskemisk) og prognose

98 pasienter med MI og EF < 45% på iskemisk grunnlag.

Fulgt i 19±8 mnd. 9 døde (3SD, 4HF, 2Inf).

Prediktorer for dårlig prognose:

ERO > 20 mm^2 i hvile.

ERO stigning under belastning > 13 mm^2.

Men: De som hadde stor MI i hvile og som fikk redusert ERO under belastning hadde god prognose.

Lancelotti et al. Circulation 2003;108:1713-1717

Primær/strukturell MI og ergoekko:

ACC/AHA:

Class IIa

Exercise Doppler echocardiography is reasonable in asymptomatic patients with severe MR to assess exercise tolerance and the effects of exercise on pulmonary artery pressure and MR severity. ***(Level of Evidence: C)***

ESC:

In experienced hands, exercise echocardiography is useful to quantify exercise-induced changes in MR, in systolic pulmonary artery pressure, and in LV function |

Surgery may be considered in asymptomatic patients with preserved LV function, high likelihood of durable repair, low surgical risk, and: • left atrial dilatation (volume index ≥60 ml/m² BSA) and sinus rhythm, or • pulmonary hypertension on exercise (SPAP ≥60 mmHg at exercise).	IIb	C

Sekundær /funskjonell MI og ergoekko:

ESC:

As ischaemic MR is a dynamic condition: stress testing may play a role in its evaluation. Echocardiographic quantification of MR during exercise is feasible, provides a good demonstration of dynamic characteristics and has prognostic importance. An exercise-induced increase of ≥13 mm^2 of the EROA has been shown to be associated with a large increase in the relative risk of death and hospitalization for cardiac decompensation [143]. The prognostic value of exercise tests to predict the results of surgery has, however, to be evaluated. The prognostic

Asymptomatisk,Høygradig Aortastenose og ergoekko

Dårlige prognostiske tegn:

- Mean gradientstigning ved belastning > 18-20 mmHg
- Manglende økning i beregnet klaffeåpningsareal
- Abnormal belastningstest (br sm, hypokinesi, EKG for, arytmi)
- Manglende kontraktil reserve (EF, Global strain, e')
- Diastolisk dysfunksjon, økning i E/e' til > 20
- PHT stigning til > 60 mmHg

Lancelotti et al. Circulation 2005, Marechaux et al, Eur Heart J 2010

Anbefalinger AVR

ESC:

AVR må vurderes hos asymptomatiske pasienter, med alvorlig AS, god VV-funksjon og gradientstigning > 20 mmHg. (Class IIb, level of evidence C).

Stress ekko gir prognostisk informasjon hos asymptomatiske pasienter med høygradig AS ved å vurdere endringer i VV-funksjon.

Magne, Lancelotti et al, Jacc Img 2014:

AVR bør også vurderes dersom PHT ved belastning.

Asymptomatiske pas med høygradig stenose og negativ stress ekko kan avvente operasjon og kontrolleres hvert år.

AHA/ACC : Nada

Ergoekko og klaffelidelser - Generelt

Økning i insuffisiens/stenose

Endringer i VV-funksjonen

Økning av trykket i lille kretsløp

Ergoekko og diastolisk dysfunksjon

- Average E/e'>14 or septal E/e'>15
- Peak tricuspid regurgitant (TR) velocity is >2.8 m/s,
- Septal e' velocity is <7 cm/s (if only lateral e' was acquired, values <10 cm/s considered abnormal)

Nagueh, Smiseth et al, ESC/AHA guidelines 2016

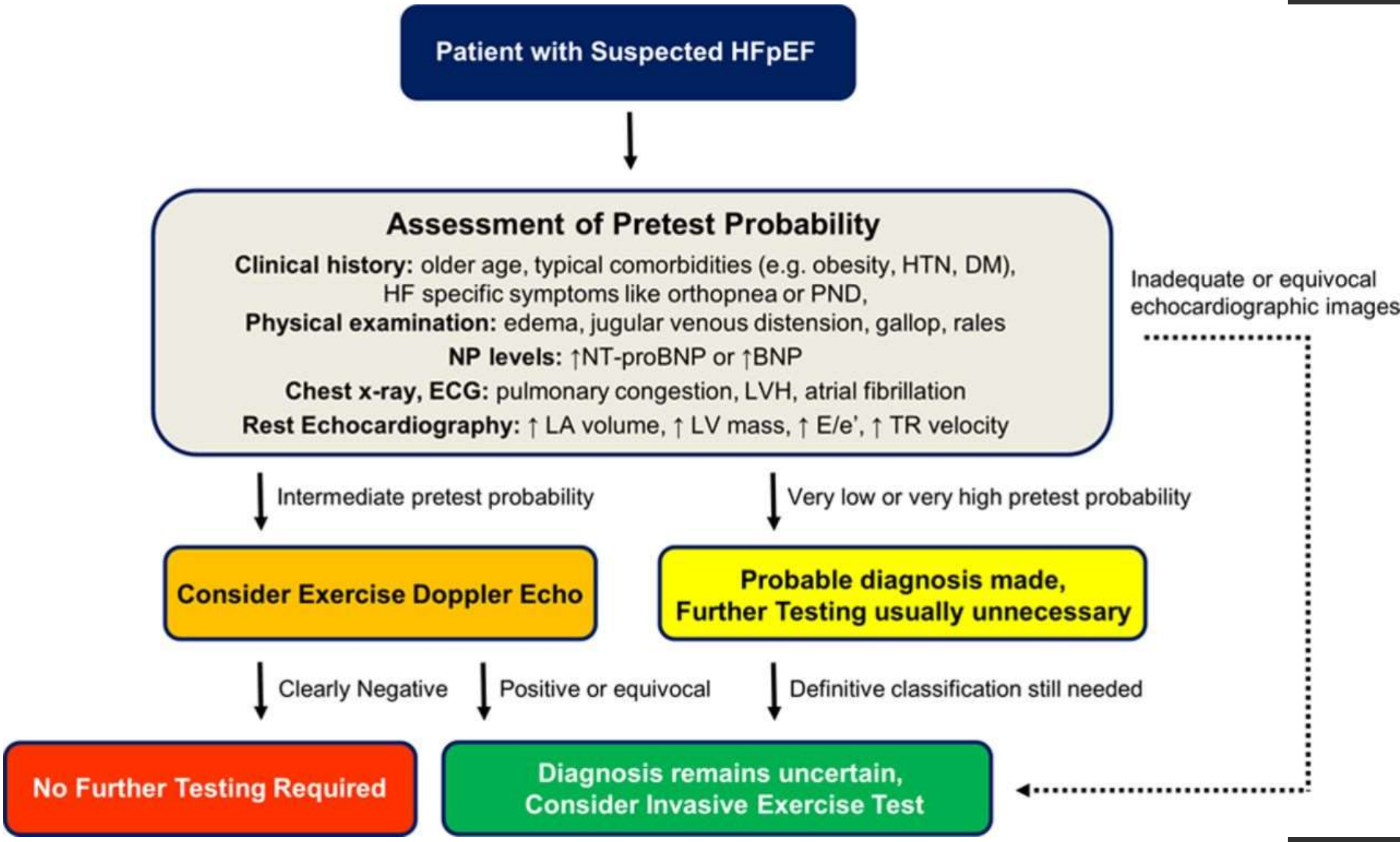
Patient with Suspected HFpEF
Assessment of Pretest Probability
Clinical history: older age, typical comorbidities (e.g. obesity, HTN, DM), HF specific symptoms like orthopnea or PND,
Physical examination: edema, jugular venous distension, gallop, rales
NP levels: ↑NT-proBNP or ↑BNP
Chest x-ray, ECG: pulmonary congestion, LVH, atrial fibrillation
Rest Echocardiography: ↑ LA volume, ↑ LV mass, ↑ E/e', ↑ TR velocity
Inadequate or equivocal echocardiographic images
Intermediate pretest probability
Very low or very high pretest probability
Consider Exercise Doppler Echo
Probable diagnosis made, Further Testing usually unnecessary
Clearly Negative
Positive or equivocal
Definitive classification still needed
No Further Testing Required
Diagnosis remains uncertain, Consider Invasive Exercise Test

Clinical use of diastolic stress echocardiography in patient with dyspnoea and reduced exercise capacity: exclusion of heart failure with preserved ejection fraction (HFpEF).

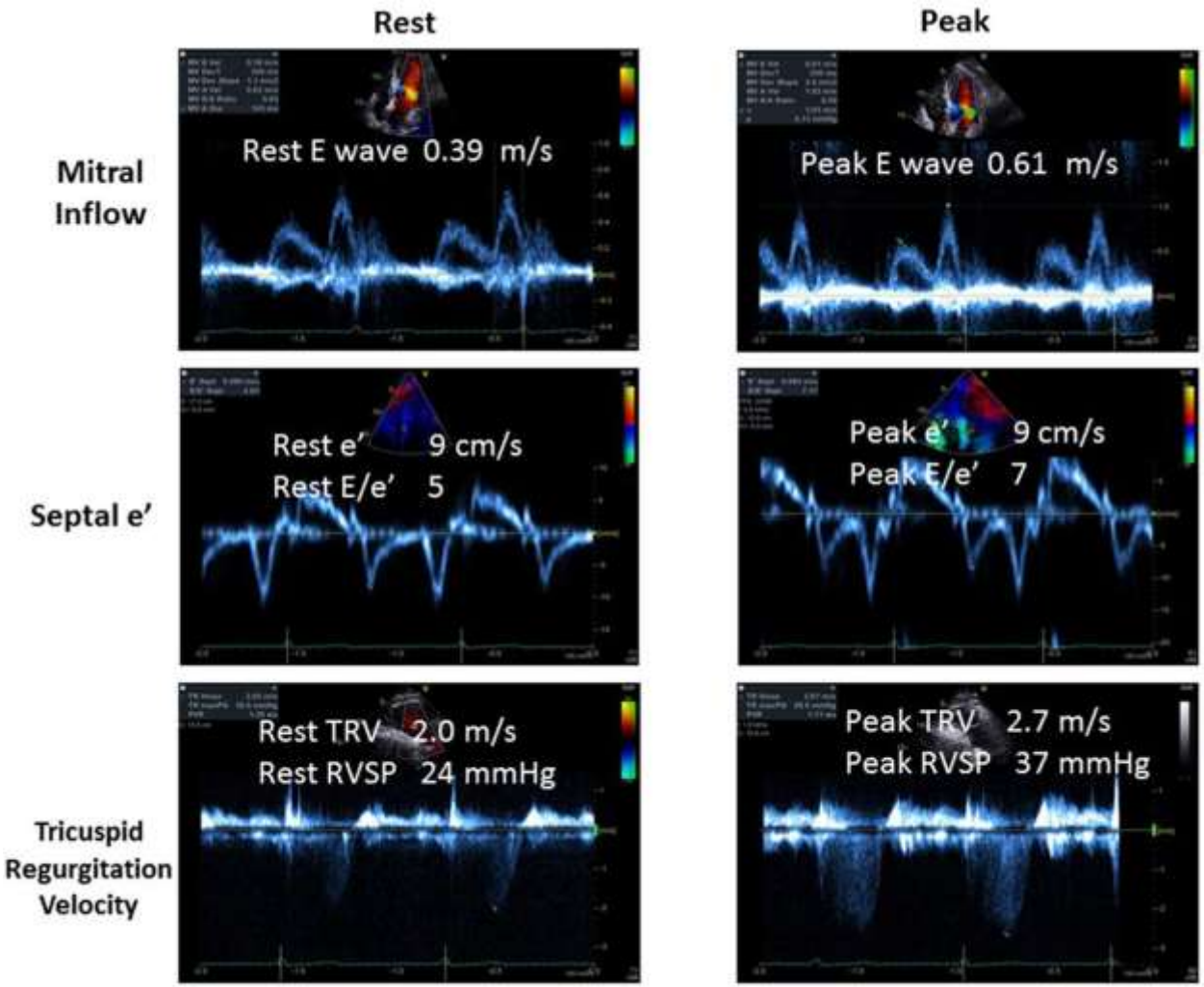

Sandhir B Prasad et al. Heart 2018;104:1739-1748

Copyright © BMJ Publishing Group Ltd & British Cardiovascular Society. All rights reserved.

Heart

Abnormal diastolic response to exercise as demonstrated by Doppler echocardiography.

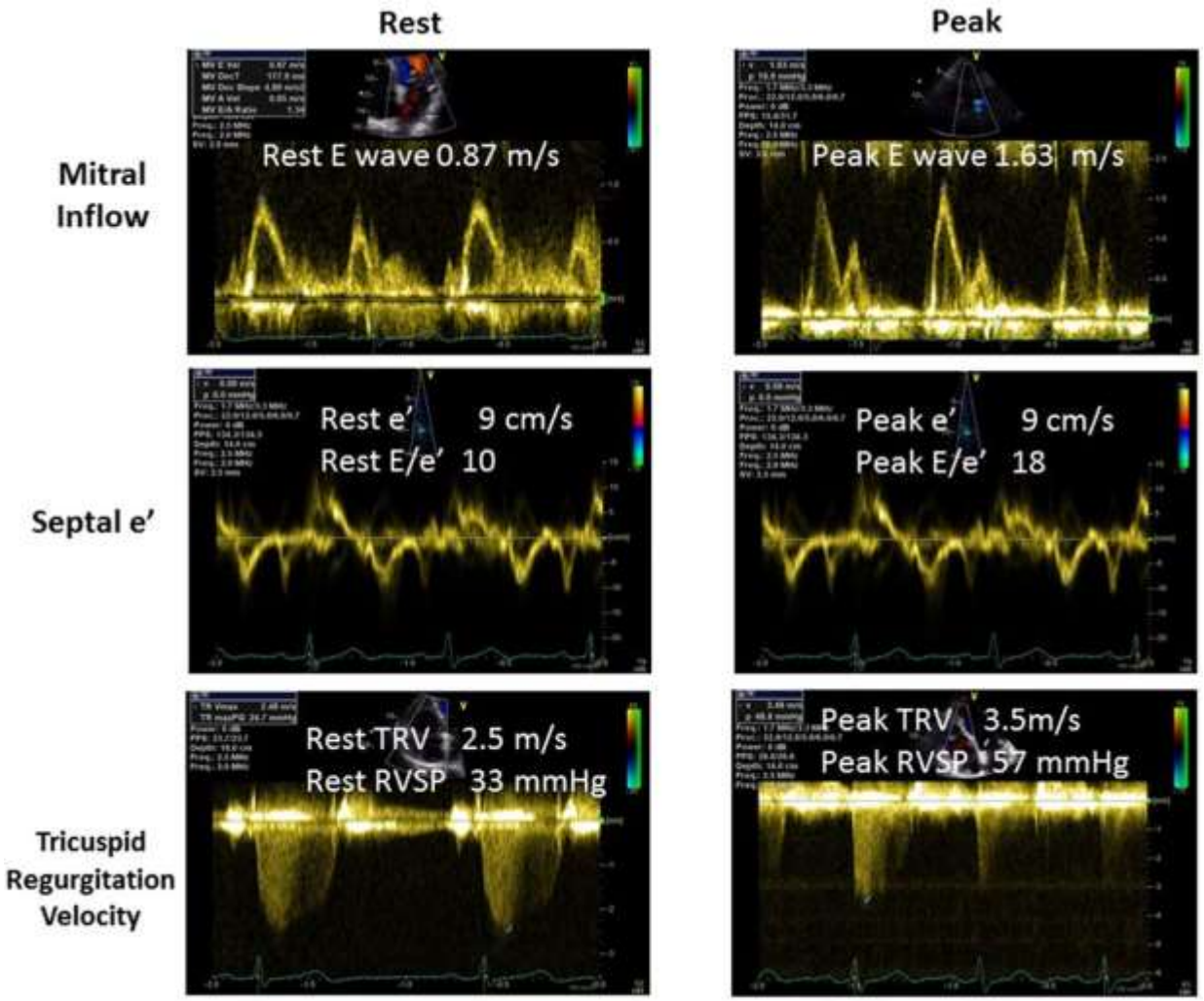

Sandhir B Prasad et al. Heart 2018;104:1739-1748

Copyright © BMJ Publishing Group Ltd & British Cardiovascular Society. All rights reserved.

Ergo ekko og pulmonal hypertensjon

- Det er normalt at lungearterietrykket stiger ved belastning pga økning i minuttvolum (hos atleter opp til 60 mmHg!)
- Grense for patologi 35 – 50 (60) mmHg
- Metoden kan brukes til å avdekke lavgradig eller latent pulmonal hypertensjon
- Metoden kan være nyttig i utredning dyspnoe

Ergoekko og medfødte hjertefeil

- Endring i shunting under belastning
- Undersøke endring i ventrikkelfunksjon og AV-klaffefunksjon under belastning
- Stigning i lungearterietrykk

Oppsummering

Ergometrisk stressekkokardiografi:

- Påvise hemodynamisk betydning av diverse hjertelidelser
- Diagnostisk avklaring / gradering
- Prognostisk vurdering
- Indikasjon for/effekt av terapeutiske tiltak

I personally would suggest government. They never go to jail.

you just lost The Game by 9GAG.COM